



PATIENT
Pippa Gilbert

PRESENTING CLINICAL SIGNS

History: Pippa was noted to have a heart murmur in August. She needs to be spayed. She is doing well with a normal appetite and energy. CV/RESP: NSR, grade IV/VI murmur with PMI left apical area radiating to right, PSS, lung fields clear. BP: 130mmHg x 3.

SPECIES
Canine

ECHOCARDIOGRAM FINDINGS

2D, m-mode, color flow and Doppler imaging is available.

BREED
Boston Terrier

Left ventricle: The LV diameter is normal with adequate myocardial function. LV wall thicknesses are normal.

SEX
Female Intact

Left atrium: The left atrium is normal.

Mitral valve: The mitral valve is normal with no prolapse into the left atrial lumen. No MR.

AGE
8 months

Aortic valve/Aorta: The aortic valve is normal in morphology and mobility. Normal aortic outflow velocity; laminar flow. No aortic insufficiency.

Right ventricle: Normal right ventricular diameter and morphology indicating no overt evidence of pulmonary arterial hypertension.

WEIGHT
20.5lbs

Right atrium: Normal RA dimension.

Tricuspid valve: The tricuspid valve appears normal with trivial physiologic tricuspid regurgitation.

Pulmonic valve/Pulmonary artery: The pulmonic valve is normal in morphology and mobility. No pulmonic insufficiency. Normal RVOT velocity; laminar flow. Suspect intermittent flow elevation on color flow imaging.

Pericardium/other: No pericardial or pleural effusion noted. No obvious cardiac masses.

Heart rhythm: ECG reveals a sinus rhythm with an average HR of 200bpm.

INTERPRETED BY

Maggie Machen
Lamy, DVM
DACVIM (Cardiology)

2-Dimensional Measurements

Ao diam (cm)	1.4
LA diam (cm)	2.1
LA:Ao (Swe)	1.5
IVS thickness (cm)	0.8
LVID diastole (cm)	2.8
PW thickness (cm)	0.8
LVID systole (cm)	1.7
FS (%)	39

Doppler Measurements

PV Vmax (m/s)	1.6
AoV Vmax (m/s)	1.5
MR Vmax (m/s)	NA
TR Vmax (m/s)	NA
TR PG (mmHg)	NA

IMAGING PERFORMED BY

Pamela Harrigan,
RDCS

HOSPITAL NAME

Mass Veterinary
Specialty Services

INTERPRETATION OF THE FINDINGS

Overtly normal cardiac dimensions and function, with no obvious dysfunction or dilation of the left heart. No significant valvular leaks are visualized and no evidence of pulmonary hypertension. No obvious congenital issues are visualized; however, it should be mentioned that small defects are easily missed. If the murmur is ausculted consistently in the future or any signs of cardiac disease develop, reassessment or referral is certainly advised. A physiologic flow murmur is suspected at this time. Prognosis is open.

REFERRING VET

Dr. Masloski

RECOMMENDATIONS

INVOICE
21274

- In an asymptomatic dog without obvious structural disease, no cardiac medications are clearly indicated.

- No cardiac contraindication for general anesthesia.

- Monitor for development of a cough, labored breathing, exercise intolerance or collapse episodes.

DATE
9/29/21



PATIENT

Pippa Gilbert

SPECIES

Canine

BREED

Boston Terrier

SEX

Female Intact

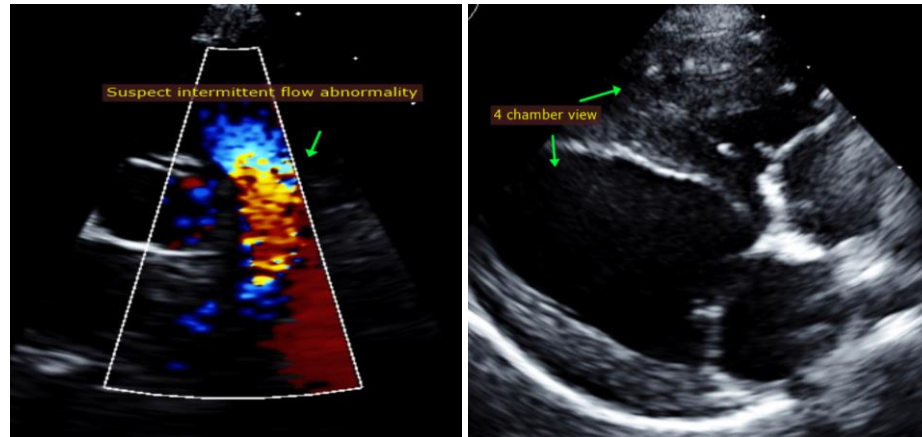
AGE

8 months

PLAN

- Assuming the murmur persists, recommend conservative monitoring with a recheck echocardiogram in 6-12 months, sooner if any development of clinical signs or the murmur progresses significantly in the interim.

IMAGES



WEIGHT

20.5lbs

The information and recommendations provided are based on the images presented by the referring veterinarian. No evaluation can be communicated regarding pathology that was not visible in the image/video clips provided.

INTERPRETED BY

Maggie Machen
Lamy, DVM
DACVIM (Cardiology)

Thank you for this referral. This report was generated using transcription software, and minor dictation errors may be present. If the clinical or image interpretation does not parallel your findings or if I can be of any further assistance, please contact me.

Maggie Machen Lamy, DVM
Diplomate of the American College of Veterinary Internal Medicine (Cardiology)
info@sonopath.com

**IMAGING
PERFORMED BY**

Pamela Harrigan,
RDCS

Echocardiogram performed by: Pamela Harrigan, RDCS
Pet Animal Ultrasound Service (4paus.com)

HOSPITAL NAME

Mass Veterinary
Specialty Services

REFERRING VET

Dr. Masloski

INVOICE

21274

DATE

9/29/21